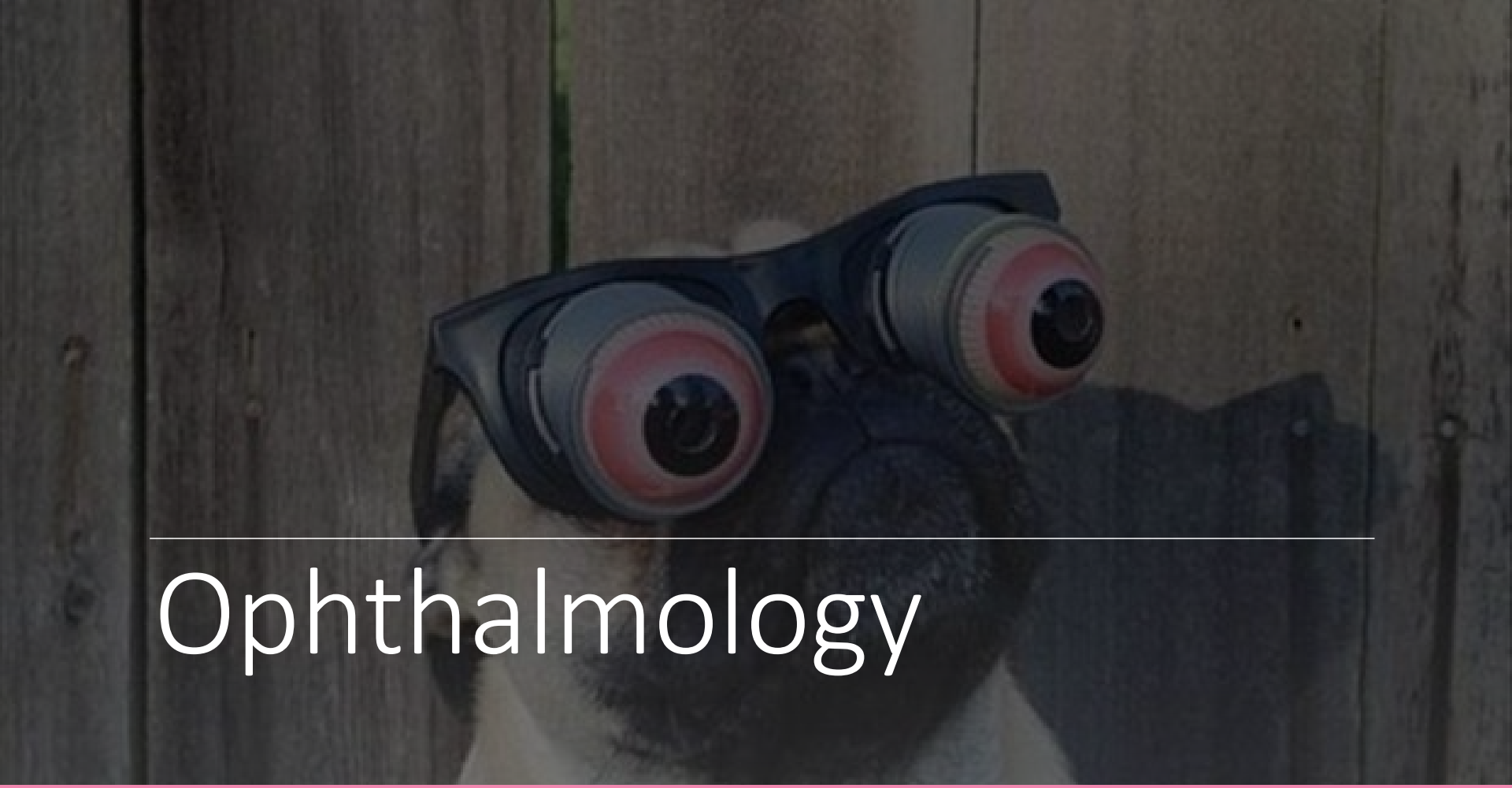

Ophthalmology

Common ophthalmic exam tests

- Fluorescein stain
- Menace response
- Palpebral reflex
- Pupillary light reflex (PLR)
- Schirmer tear test (STT)
- Tonometer

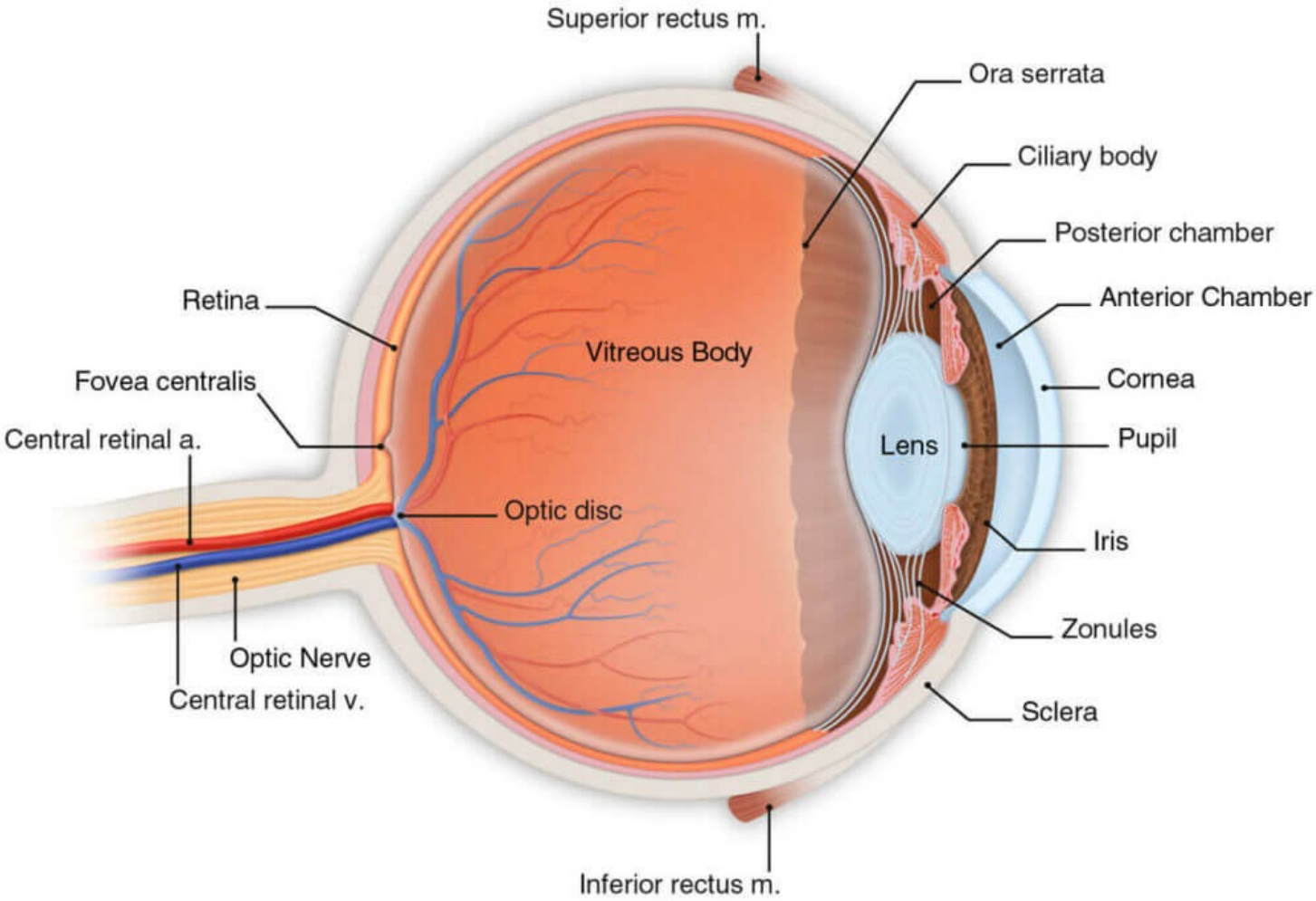
Superior rectus m.
Ora serrata
Ciliary body
Posterior chamber
Anterior Chamber
Cornea
Pupil
Iris
Zonules
Sclera
Inferior rectus m.
Retina
Fovea centralis
Central retinal a.
Optic Nerve
Central retinal v.
Vitreous Body
Optic disc
Lens

Lacrimal System

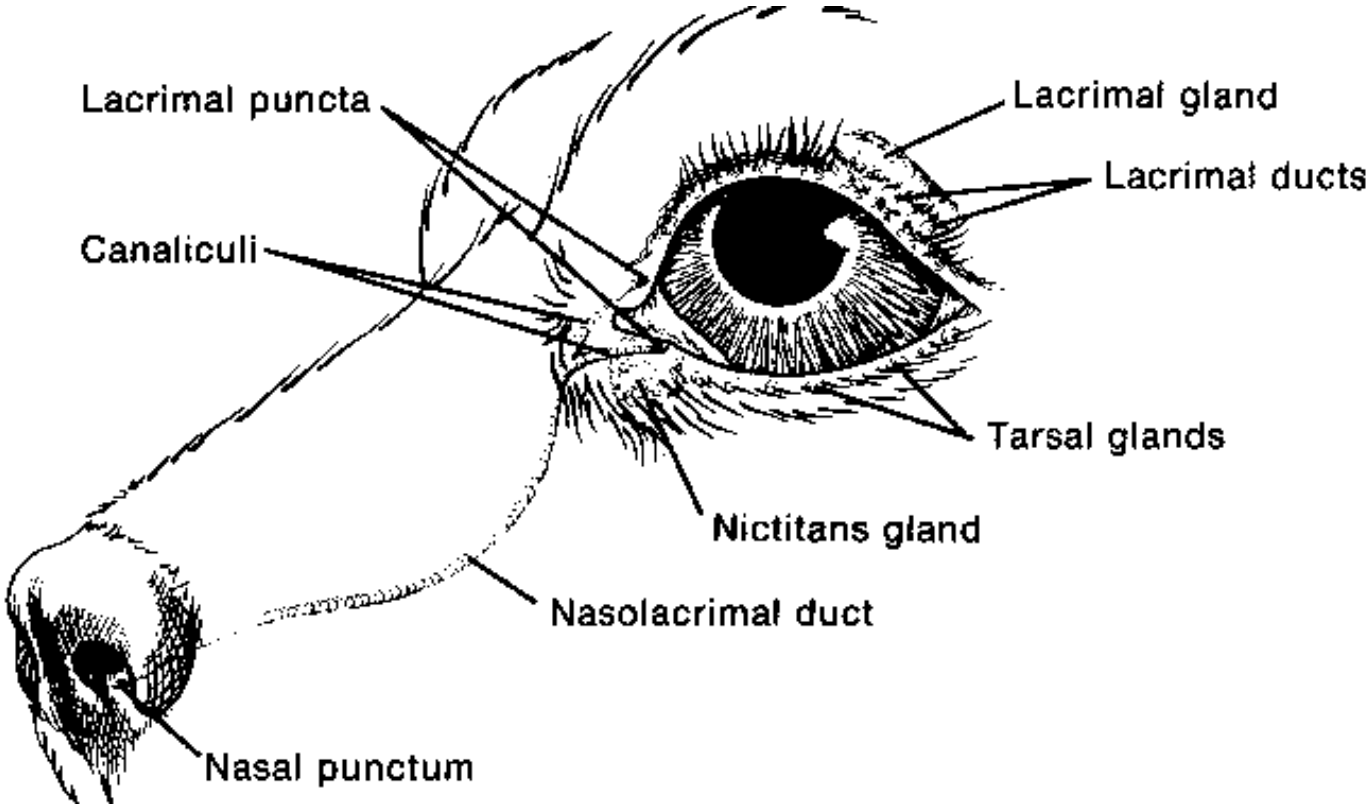

Before you start an ophthalmic exam, assess if the patient is visual…

- Can the patient see?
  - How to assess?
    - Navigation of room,
    - Throw cotton balls
    - Menace response
      - This is not a reflex! It is a learned response. Very young puppies and kittens will not have this response.
      - Any other reason patient cannot blink?

Examination of the Eye

- Redness, Swelling, Discharge
  - Note symmetry, and character
- Eyelids/Eyelashes
  - Opening normally? Masses? Ectopic cilia? Entropion (lower eyelid rolling in toward the eye)? Ectropion?
- Symmetrical pupils?
  - Terms: Anisocoria, Strabismus, Nystagmus
- Enlarged or protruding eyes
  - Glaucoma, mass behind the eye
  - Can you retrobulbar press globe?
- Exophthalmos
- Enophthalmos

Ocular Reflexes

- **Corneal Reflex**
- **Palpebral Reflex**
  - **If too deep under anesthesia, this reflex maybe lost**
- **Menace Reflex**
- **Doll's Eye Reflex**
- **Nystagmus**
  - Caused by improper function of a nerve
  - Can be genetic (common in Siamese and Himalayan cats)
- Dropping cotton balls or other light material in front of their face to see if they watch it fall
  - Cannot use items that make noise- will not only test sight at that point= CHEATING!!

Schirmer Tear Test

- Measures the amount of tears produced
- Perform prior to other tests
- <u>Normal values</u> = 15 - 20 mm

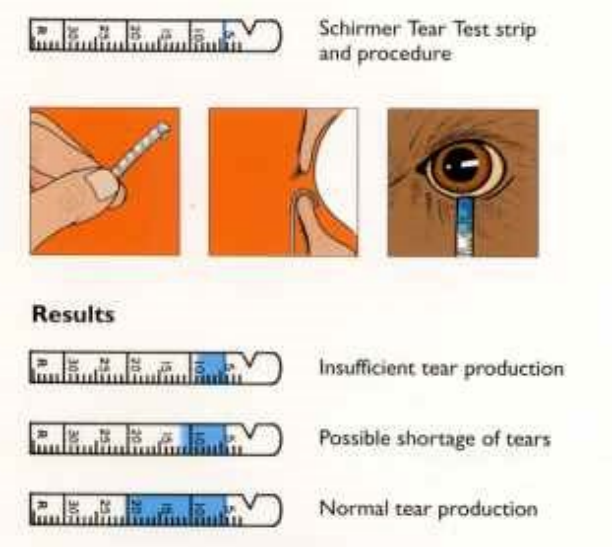

Fluorescein Dye

- Checks for corneal ulcers
- Checks the patency of the lacrimal system
- Wood's light or cobalt filter may be used to illuminate the dye and make reading easier
- Supplies
  - ❑ Stain
  - ❑ Eye wash
  - ❑ Cotton or gauze
  - ❑ Sterile saline
  - ❑ Black light
  - ❑ Proparacaine
  - ❑ Good restraint- what do you want to be mindful of?

Ophthalmoscope

- Used to *directly examine the internal structures of the eye.* Magnification = 15X.
- Green Filter – provides better contrast of red blood vessels
- Slit Lamp = helps determine “cloudiness” in anterior chamber
- UV light = helps highlight fluorescein stain



Ophthalmic Instruments

- **Indirect Ophthalmoscopy**
  - **Better view of retina**
- **Transilluminator**
  - Bright, focused, light, may have cobalt blue cap
- **Shiotz or Pen Tonometer**
  - Measures intraocular pressure of eye

Tonopen

- To measure intraocular pressure (IOP)
- Items needed for this test:
- ❑ Tonopen
  - ❑ May need to calibrate machine first
- ❑ Tonopen cover
- ❑ Proparacaine
- ❑ Good restraint
- Need to know how to read results
- Glaucoma is suggested at a reading over 30mmHg
  - IOP normals:
    - Canine = 16-30 mmHg
    - Feline 14-26 mmHg

OCULAR CONDITIONS & DISORDERS



Eyelid Abnormalities

- **Entropion**
  - Turning inward of the eyelid - can cause corneal ulcers.
  - Breeds prone = St. Bernard, **Sharpei, Chow Chow**
- **Ectropion**
  - Turning outward of the eyelid - causes conjunctivitis.
  - Breeds prone = **Bassets, St. Bernards, Boxers**
- Usually **genetic** or **congenital**
- **Tx**: Surgery if causes problem

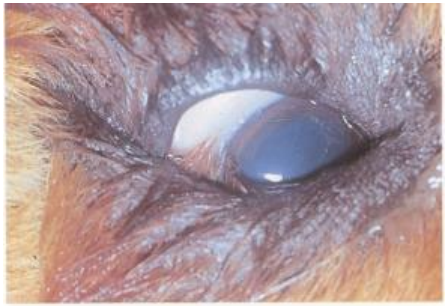

Blepharitis

- **Inflammation of the eyelid.**
- **Causes**:
  - **Trauma**
  - **Bacteria -** common in dogs & cats
  - **Fungus -** common in horses
  - **Allergies** (seen after vaccinations, bee stings, etc.)
  - **Parasites** - Thelazia sp.
- **Treatment**:
  - Anti-inflammatory drugs combined with antimicrobial or antifungal agents

Epiphora

- Excessive Tearing
- Results in staining of the medial canthus hairs - is more pronounced in lighter coated dogs.
- May cause dermatitis with inflammation
- **Cause**:
  - Genetic
  - Increased Production - Irritation
  - Blocked Drainage - Puncta or Nasolacrimal duct
- **Treatment**:
  - Flushing the puncta and nasolacrimal duct
  - Removing inciting cause

Neoplasia

- **Squamous Cell Carcinoma -** Malignant
  - Eyes, ears, nose
  - Called “Cancer Eye” in Large animals
- **<u>Treatment</u>**
  - Usually requires surgical removal
  - Benign or Malignant
  - Causing disturbance of function

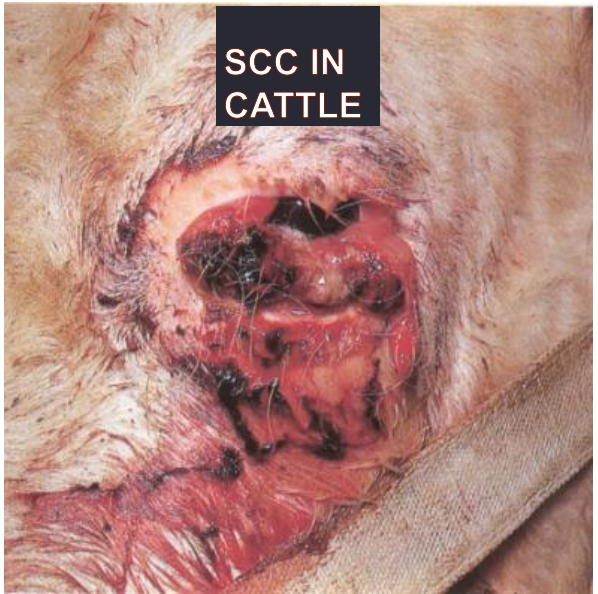

Cherry Eye

- Protrusion of the 3rd Eyelid or its gland
- Results in abrasion and drying of the gland and possible damage to the cornea.
- May result in KCS
- **Cause**
  - genetic, traumatic, or allergic
- **Treatment**
  - Surgical replacement
  - May have to be removed in severe cases

3RD EYELID & FOLLICLES

Foreign Bodies

- Can be any type of foreign material into the eye
- Usually is associated with trauma
- Commonly causes ulcerations
- Nomally seen with the naked eye unless hiding under 3rd eyelid!

Proptosed Eye

- A medical emergency, especially if you want to save vision
- Must anesthetize patient and replace eye into socket
- The veterinarian will suture part of the eyelid closed to ensure the eye stays where it belongs.
- Study suggest 60% of canine and 100% of felines will lose vision in that eye.

Lens Abnormalities

- Loss of transparency of the lens due to the buildup of a protein material
- **Nuclear sclerosis** is an age related change that does not usually affect vision.
- **Cataracts** block light passage and decrease vision.
  - **Location on the lens** - capsular or subcapsular
  - **Age of onset** - congenital, developmental or juvenile, senile or senescent.
  - **Cause** - traumatic, genetic
  - **Degree of Maturation**

Horner's Syndrome

- Combination of four clinical signs:
  - Ptosis (drooping of upper eyelid)
  - Miosis (pupil constriction)
  - Elevated third eyelid
  - Enophthalmos (globe sunk back into socket)
- Often acute and unilateral
- Caused by denervation of sympathetic pathways
- Multiple etiologies (trauma, neoplasia, infection, others)

Retinal Detachment

- A separation of the retina from the choroid
- May be congenital or due to trauma, infectious diseases, hypertension, or neoplasia.
- **Signs**:
  - Loss of vision, appearance of retinal vessels through the pupil, increased blood pressure.
- **Treatment**
  - Diuretics to reduce edema, antihypertensive meds, antibiotics, and corticosteroids.
  - Surgery may be needed

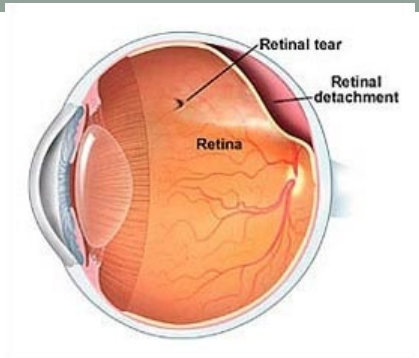

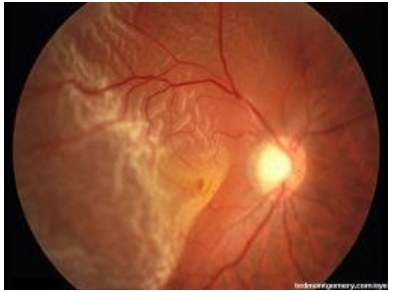

Retinal hemorrhage

- Bleeding into retina
  - Blood vessels of retina or choroid
  - Congenital deformities (Collie eye anomaly)
  - Circulatory disorders
  - Clotting abnormalities
  - Infection/ inflammation
  - Neoplasia
  - Trauma
- **Signs**:
  - Mild
    - No obvious signs
  - Severe
    - Decreased vision, dilated pupils
- **Treatment**
  - Treat underlying condition

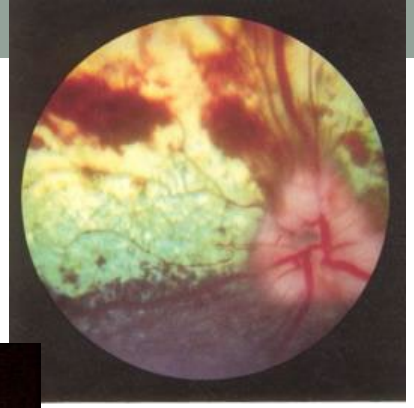

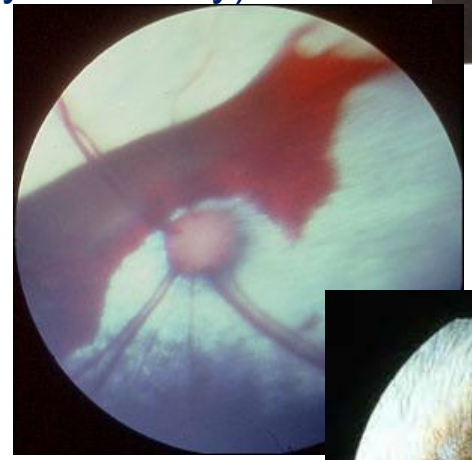

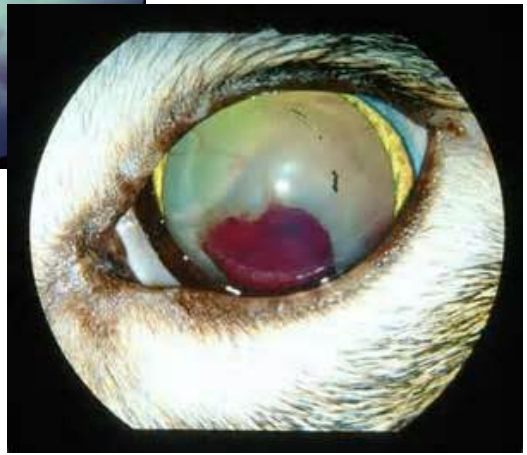

Conjunctivitis

- Inflammation of the conjunctiva.
- **Causes**
  - Allergic
  - Infectious - Canine Distemper or Chlamydia
  - Immune mediated
- **Signs**
  - **pruritus** and alopecia of the surrounding area
  - Increased tear production and pain
- **Treatment**
  - Eliminate cause or minimize inflammation
    - Topical steroids

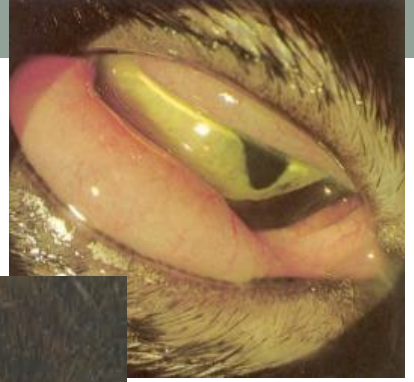

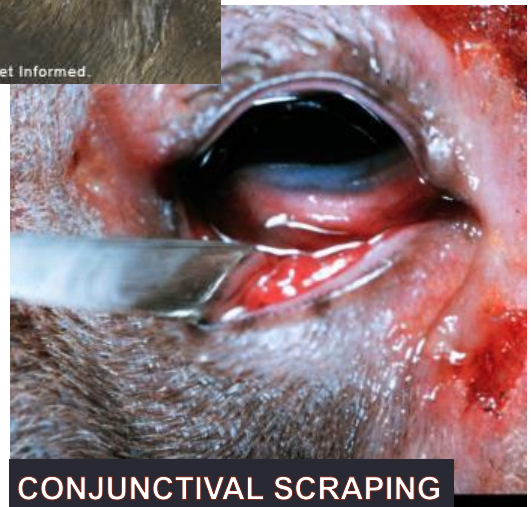

Keratoconjunctivitis Sicca

- Decrease in tear production
- Drying out of the cornea and a mucoid film over the eye.
- Brachycephalic
- Common in older dogs and may be caused by drugs (e.g. Sulfa drugs) or immune mediated.
- Dx: Less than 10 mm on a Schirmer tear test
- **Treatment**
  - Medical - topical cyclosporine (Optimmune)
  - Surgical - **Parotid Duct Transplant**

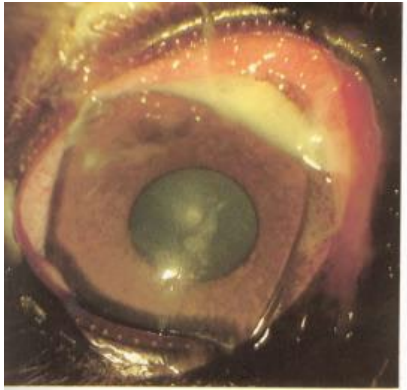

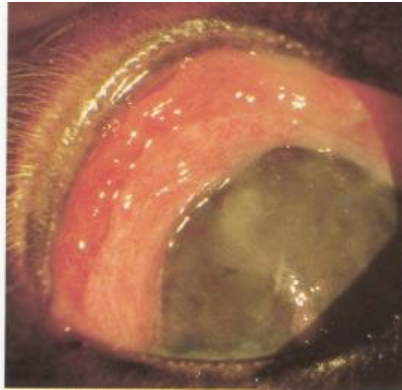

Corneal Edema/Ulceration

- **Signs**
  - Edema, vascularization, scar formation, pigment deposition, pain, blepharospasm and cellular infiltration.
- **Causes**:
  - Trauma (incl. Foreign body), infections (bacterial, fungal viral-ICH, Herpes, chronic glaucoma, radiation, drugs, burns and hypotonic solutions
- **Treatment**:
  - Topical antibiotics and mydriatics (dilate the pupil).
  - May require surgery if severe or non-healing.
  - **NEVER** use corticosteroids
    - Interfere with healing
    - Will make ulcer worse

Glaucoma

- **Increase** in the **intraocular** pressure
  - Increased production of Aqueous Humour
  - Decreased Drainage - due to blockage
- **Signs**:
  - Corneal edema, enlarged vessels, dilated pupil, vision loss, swelling of the eye (buphthalmos), ocular pain, loss of corneal sensitivity.
- **Treatment**:
  - Long-term administration of drugs
  - Diuretics to remove excess fluids
  - Miotics (Pilocarpine) **-** constrict pupil so iris doesn't block passage of aqueous humor from cilary body to anterior chamber
    - Prevents buildup of aqueous humor in posterior chamber

Uveitis

- An inflammation of the middle layer of the eye (uvea).
- The most common type is an inflammation of the iris called iritis (anterior uveitis).
- Symptoms include redness, pain, light sensitivity, blurred vision, and dark floating spots in the field of vision.
- Look for flare with slit lamp.

Common Surgical Procedures

- **Conjunctival or 3rd Eyelid Flap**
  - **A flap of conjunctiva is sutured over the globe to provide a temporary covering for the eye**
  - Used in corneal ulcers with prolonged healing
  - Buttons or tubing may be used with tension sutures to prevent tearing of the thin conjunctiva.

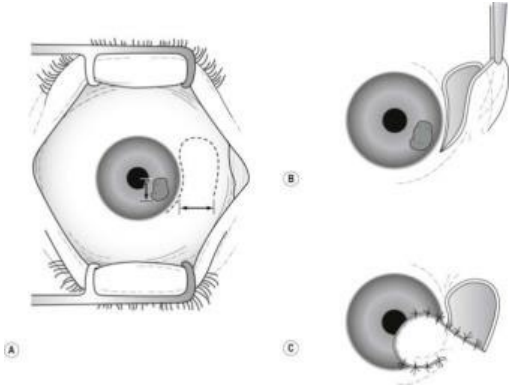

Common Surgical Procedures

- **Enucleation**
  - **Removal of the entire globe**
  - An intra-ocular prosthesis may be used to maintain more normal appearance of the eye.

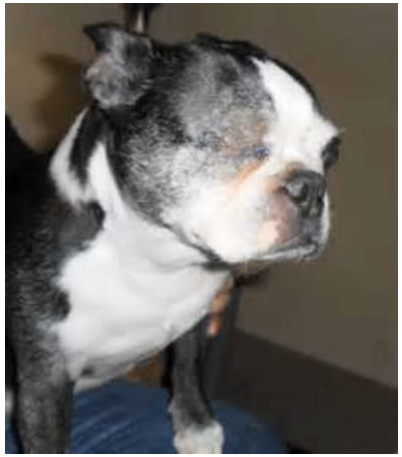

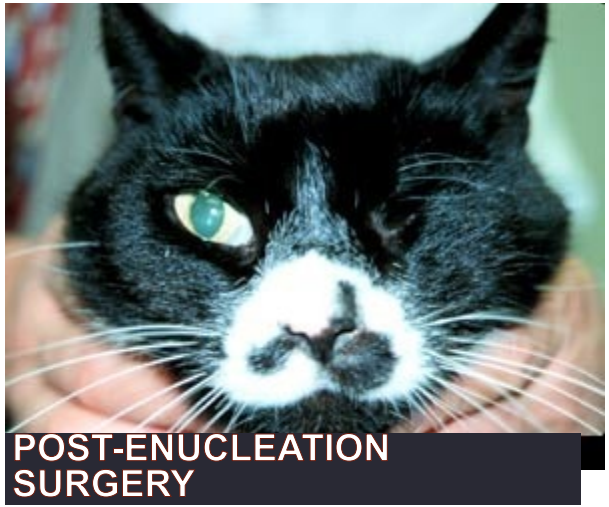

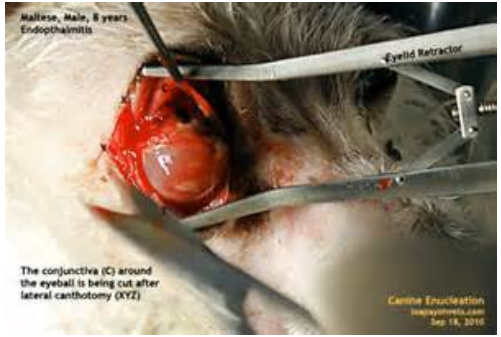

Intrascleral Prosthesis

Ocular Administration Routes

- **Topical -** most common route.
  - Make sure tip does not come in contact with eye
    - Transfers microbials, idiopathic conditions, scratch the cornea
  - Should be applied no less than 3-4 times a day
  - **Drops**
    - Try to hit center of the eye
    - Penetrate faster than ointments
  - **Ointments**
    - Place on lower conjunctiva
    - Stays in eye longer and do not tear out as easily

Ocular Medications

- Antimicrobials
- Miotics
  - Pupil constriction
  - Glaucoma
- Mydriatics
  - Pupil dilation
- Anti-inflammatory: Steroids

THAT'S ALL OPHTHALMOLOGY!